



## Radiology

Lec.3

Dr. Ahmed Jamal

### Intra oral projection

#### ❖ Periapical radiography

The name *periapical* is derived from the Greek *peri*, which means "around," and *apical*, which means "tip."

#### Indications:

1. Detection of apical infection.
2. Assessment of periodontal status after trauma to the teeth and alveolar bone
3. Assessment of presence and position of un-erupted teeth.
4. Assessment of root morphology.
5. During endodontic.
6. Bone evaluation in pre surgical implant insertion.

**There are two commonly used intra oral techniques :**

**a/ Bisecting technique:** Is the older and the easier of the two techniques.

**b/ Parallel technique:** It was originally developed by MC Cormack. The result of this technique is superior to those of bisecting one.

#### **Theory of parallel technique :**

It called so because film and the tooth must be parallel to each other. The requirements of this technique are:-

1. It requires the target object distance as long as possible and practical.
2. It requires the X-ray strike the object (tooth) and the film at right angle (90°).

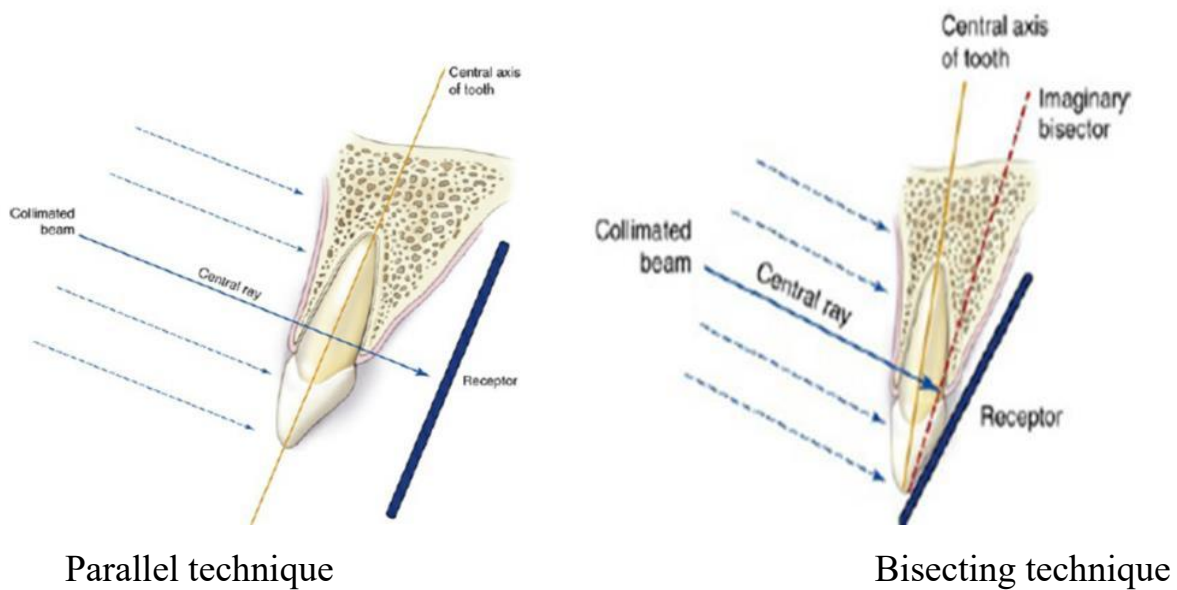
3. It requires the film to be placed in a position parallel with the plane passing through the long axis of all teeth being examined.

The last requirement necessitates fairly wide separation of the tooth and the film, which produce considerable distortion (magnification) if the short target – object distance were employed. However, the use of extended long cone of 16 inches will increase the target–object distance and compensates for the distortion and un sharpness that result from increasing object – film distance.

### **Theory of bisecting technique:**

1. Operator envisions an imaginary bisector of the angle formed by the long axis of the tooth and the long axis of the film, this angle is formed where the film contacts the tooth crown.
2. Operator direct the central ray of the beam through the apex of the tooth so central ray strikes the bisector at  $90^\circ$  , such angulations if properly employed results in a tooth image that is exactly the length of the object.

In this technique, as a result of lack of parallelism between the tooth and the film since the film is in contact with the tooth crown, we have all the areas below the apex of the tooth as well as above are distorted and the degree of distortion can reduced by the use of long cylinder because the longer distance between the source of radiation and the object the more is the parallel will be the rays.



Comparison between parallel and bisecting techniques

**Identification dot:** It's a round raising dot present in the corner of each film, allows rapid and proper film orientation and placement . The manufacturer orients the film in the packet so that the convex side of the dot is toward the front of the packet and faces the source of radiation. During film exposure , the film oriented to place the dot 2-3 mm away from the incisal or occlusal surface.

### Horizontal and vertical angulations

1. **Horizontal angulation:** refers to X-ray beams direction in a horizontal plane.
2. **Vertical angulation:** refers to X-ray beam direction in a vertical plane.

**Plus vertical angulation:** when the beam is tipped down ward

**Minus vertical angulation:** when the beam is tipped upward.

### ❖ Film placement and angulations for periapical films:

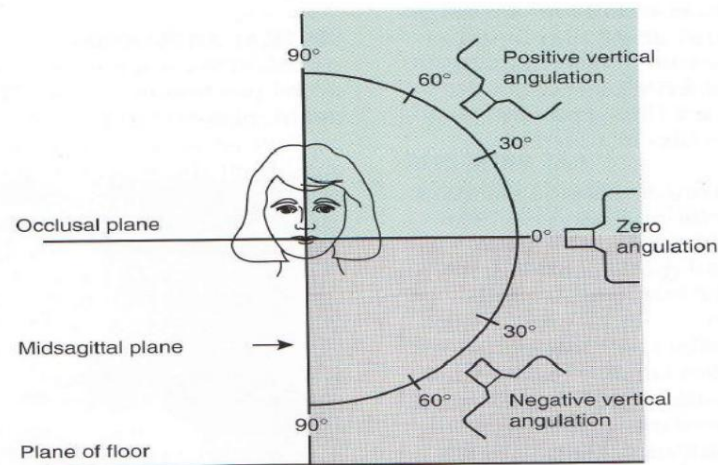
The anatomical area and the apex of the tooth under investigation should be shown, as well

as 2-3mm of surrounding bone to enable an assessment of apical anatomy.

## Angulations guidelines for bisecting angle projections

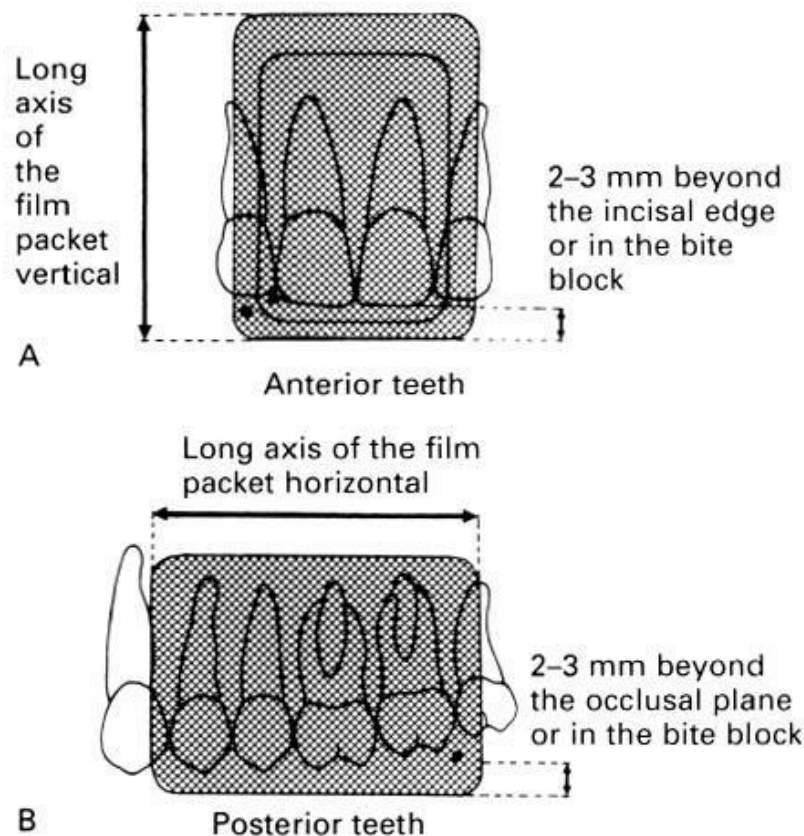
| projection | Maxilla     | mandible    |
|------------|-------------|-------------|
| Incisors   | + 40 degree | - 15 degree |
| Canines    | + 45 degree | - 20 degree |
| Premolars  | + 30 degree | - 10 degree |
| Molars     | + 20 degree | - 5 degree  |

\*when occlusal plane is oriented parallel with the floor



## The point of entry of central ray for each tooth

| Area                    | Point of entry   |
|-------------------------|--|
| <b>central incisors</b> | Direct the central ray high on the lip, in the <u>midline</u> , just below the septum of the nostril |
| <b>lateral incisors</b> | Orient the central ray to enter high on the lip about <u>1 cm</u> from the midline                   |
| <b>premolars</b>        | This point is usually <u>below the pupil</u> of the eye  |
| <b>molars</b>           | should be on the <u>cheek below the outer canthus of the eye</u>                                     |



Diagrams showing the general requirements of the film packet position (periapical film) for A anterior and B posterior teeth.

#### ❖ **Film placement and angulations for bitewing films:**

Bitewing X-ray film used to show the inter proximal caries and visualize the periodontal condition, in adult we need 2 bitewing film on each sides of the jaw at premolar

and molar area while in children of 12 years old we need one film on each side.

\* Patient is positioned with the occlusal plane horizontal and the tab of the film placed on the occlusal surfaces of lower teeth ask the patient to close the teeth firmly together on the tab the beam is aimed directly through the contact areas at right angles to the teeth and film in horizontal plane and at approximate  $5^{\circ}$  -  $8^{\circ}$  downward in vertical plane.

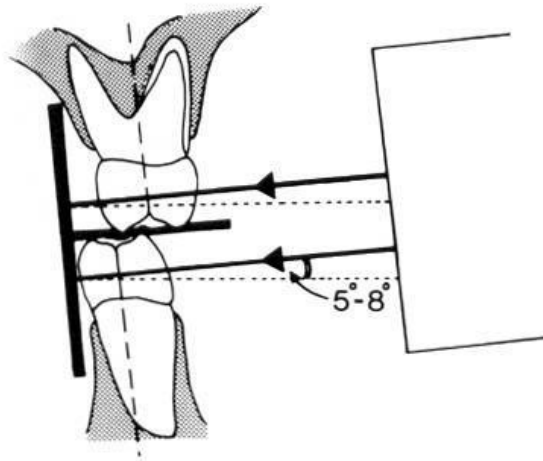


Diagram showing the ideal film packet position and the approximate 5°-8° downward vertical angulation of the X-ray beam compensating for the curve of Monson

### ❖ Occlusal film projection:

#### **Diagnostic Objectives of Occlusal Radiography**

- To locate supernumerary, un erupted, and impacted teeth
- To localize foreign bodies in the jaws and floor of the mouth
- To identify and determine the full extent of disease (e.g., cysts, osteomyelitis, malignancies) in the jaws, palate, and floor of the mouth
- To evaluate and monitor changes in the midpalatal suture during orthodontic palatal expansion .
- To detect and locate sialoliths in the ducts of sublingual and submandibular glands

#### **Types of occlusal projection**

1. Maxillary occlusal projections
2. Mandibular occlusal projections

#### **Maxillary occlusal projections include:**

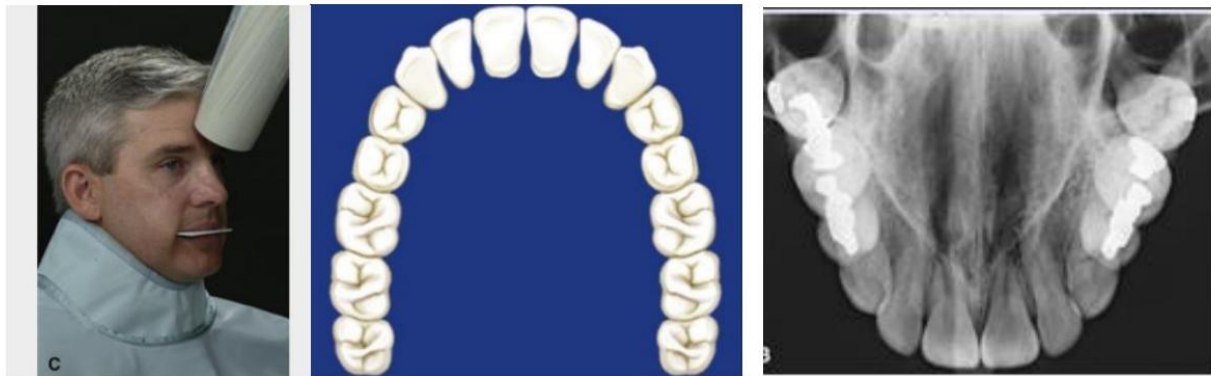
- a- Upper standard occlusal
- b- Upper oblique occlusal
- c- Vertex occlusal.

#### **A - Upper standard occlusal**

This projection shows the anterior part of maxilla and upper anterior teeth.

### **The technique:**

1. Patient position where the occlusal plane horizontal and parallel to the floor.
2. Film placed on to the occlusal surfaces of lower teeth and patient asked to bite together gently the film place centrally in the mouth (the long axis crossways).
3. X-ray tube positioned above the patient in the midline directed downward through the bridge of the nose at  $65^{\circ}$  -  $70^{\circ}$  to the film packet.

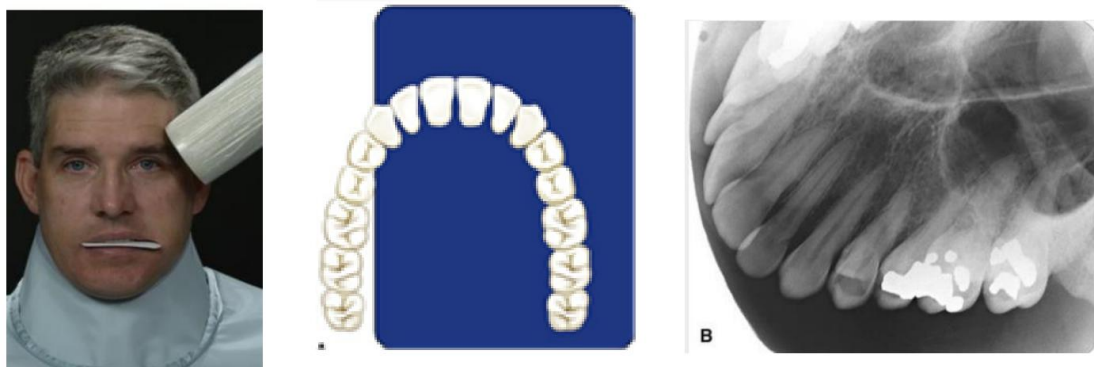


### **B – Upper oblique occlusal**

This projection shows the posterior part of maxilla and the upper posterior teeth.

### **The technique:**

1. Patients position where the occlusal plane horizontal and parallel to the floor.
2. Film placed on the occlusal surfaces of lower teeth with long axis anterior posterior it placed to the side of the mouth under examination and patient asked to bite gently.
3. X-ray tube positioned at the side of patients face directed downwards through the cheek at  $65^{\circ}$  -  $70^{\circ}$  to the film.

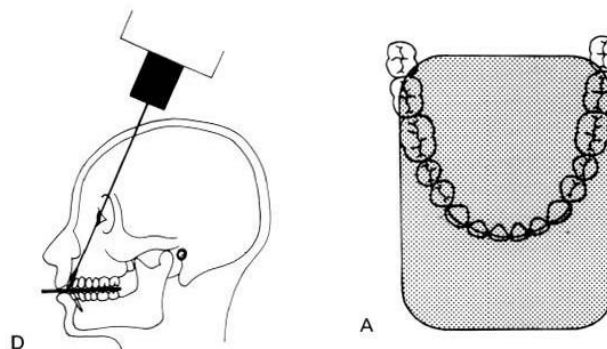


### **C- Vertex occlusal:**

This projection shows a plan view of teeth bearing area of maxilla from above to assess the bucco - palatal position of un erupted canines.

#### **The technique:**

1. The patient is seated with occlusal plane horizontal and parallel to the floor.
2. The film placed on the occlusal surfaces of lower teeth with its long axis anteroposteriorly and patient asked to bite on to it.
3. X-ray tube is positioned above the patient in the midline directed downwards through the vertex of the skull.



### **Mandibular occlusal projection:**

- a/ Lower 90° occlusal (true occlusal).
- b/ Lower standard occlusal.
- c/ Low oblique occlusal.

#### **a/ Lower 90° occlusal (true occlusal):**

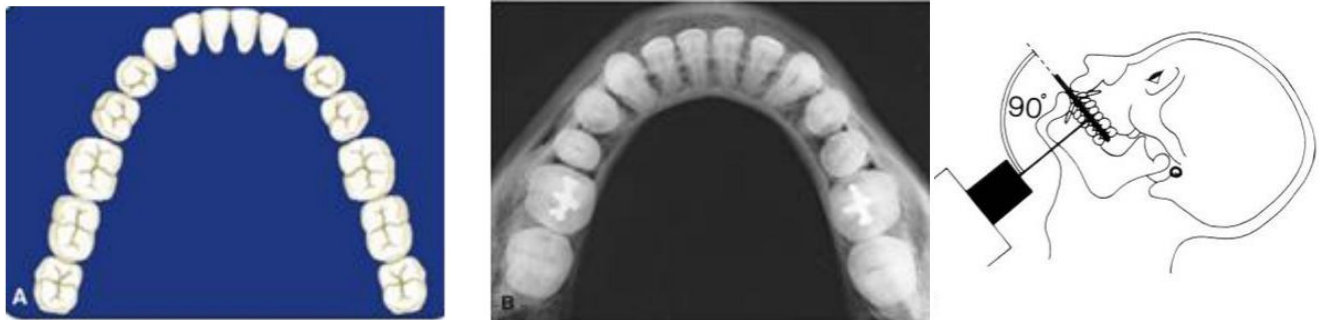
This projection used to show a plan view of the tooth bearing area of mandible and the floor of the mouth.

#### **\* The technique:**

1. Patient tips his head backward as far as comfortable, where it is supported.
2. The film placed centrally into the mouth on the occlusal surfaces of lower teeth with long axis crossways and patient bite gently on the film.



3. X-ray tube placed below the patients chin in midline centering on imaginary line joining the first molar at 90° to the film.

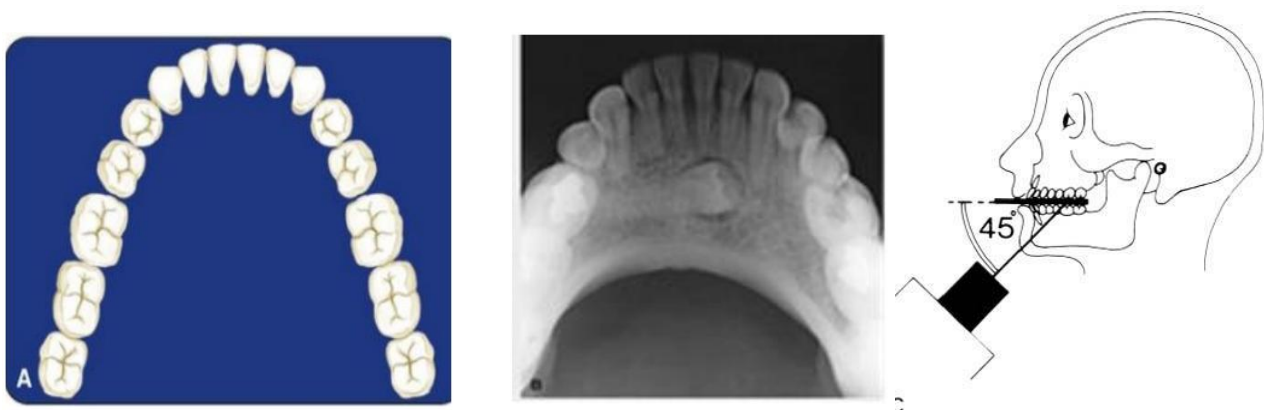


#### **b/ Lower standard occlusal:**

This projection is taken to show lower anterior teeth and anterior part of mandible.

#### **\* Technique:**

1. Patient is seated with the head supported and occlusal plane horizontal and parallel to the floor.
2. Film placed centrally into the mouth and the long axis anteroposterior then asks him to bite on the film gently.
3. X-ray tube positioned in midline centering through the chin point at 45° to the film.



### **Lower oblique occlusal:**

This projection shows the submandibular salivary gland on the side of interest.

#### **\* The technique:**

1. Patients head is supported and rotated away from the side under investigation and raised.
2. The film placed on occlusal surfaces of lower teeth over to the side under investigation with long axis anterior posteriorly then he bite on the film gently.
3. X-ray tube directed upwards and forwards toward the film from below and behind the angle of mandible and parallel to the lingual surface of the mandible.

