

Permanent Maxillary Central Incisor

Permanent incisors

Permanent incisors are eight in number; four in maxilla and four in mandible. The major function of the incisors is to incise or cut the food during mastication process. In addition, they play important roles in phonetics (speech), supporting the lips, and maintaining a desirable esthetic appearance.

Characteristics of incisors (crown aspect):

1. Incisal ridge and edge.

Incisal ridge: is that portion of the crown which makes up the complete incisal portion.

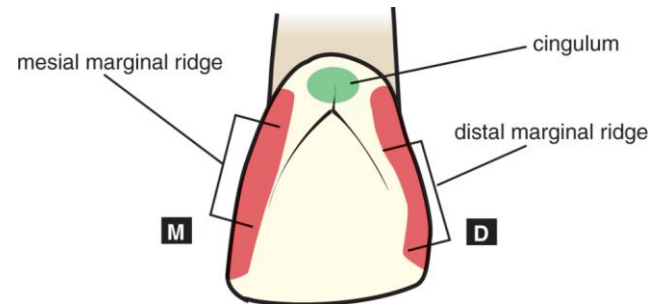
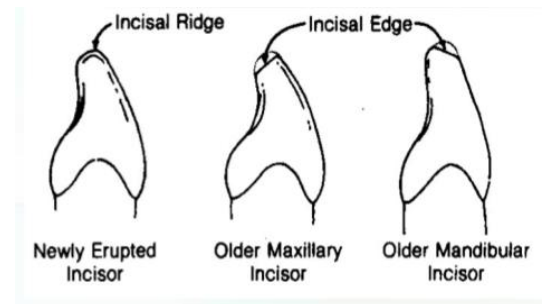
Incisal edge: is used when an angle is formed by the occlusal wear which creates a flattened surface linguo-incisally.

2. Cingulum.

3. Marginal ridges are longitudinally positioned.

4. Lingual fossa.

5. Presence of mamelons (on the incisal ridge).



Permanent Maxillary Central Incisor

The maxillary central incisors are wider and larger than the maxillary lateral incisors and wider than both of the mandibular incisors. they can be identified by the following characteristics:

1. They are the widest anterior teeth mesio-distally (labial or lingual surface).

2. They have a square or rectangular appearance.

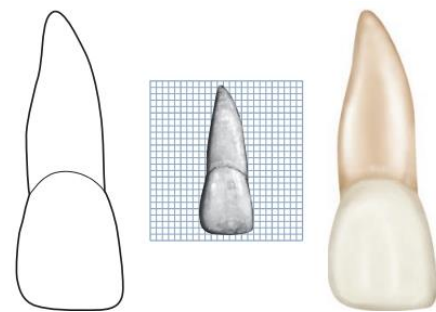
3. Straight mesial outline, and rounded distal outline.

4. Sharp mesio-incisal angle and rounded disto-incisal angle.
5. Mamelons on the incisal ridge (in newly erupted teeth).
6. Well-marked marginal ridges, lingual fossa and well-developed cingulum.
7. Single tapered root.

Aspects of maxillary central incisor:

1. Labial Aspect:

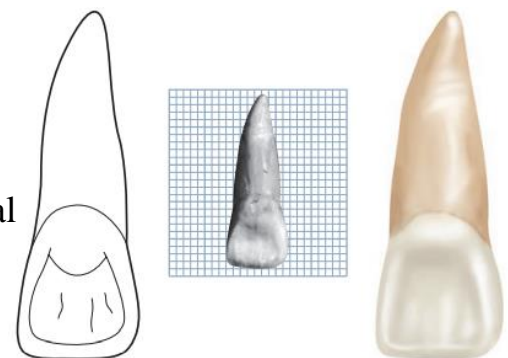
1. The mesial outline is slightly convex with a crest of curvature near the mesio-incisal angle.
2. The distal outline is more convex than mesial outline with the crest of curvature being at the junction between incisal and middle thirds.



3. The incisal outline in newly erupted teeth has elevations called "Mamelons". With age, they will wear off and straight incisal outline will be seen.
4. The cervical outline of the crown follows a semi-circular direction with the curvature directed towards the root.
5. The root is cone shaped with a blunt apex. It is 2-3 mm longer than the crown.
6. A line drawn through the center of the root and crown tends to parallel the mesial outline of the crown and root.

2. Lingual Aspect:

1. The crown and root taper lingually, therefore, mesio-distal dimension of the lingual surface is narrower than that of the labial surface.



2. Below the cervical line, there is a smooth convexity called "Cingulum" which is confluent with raised marginal ridges mesially and distally.

3. Incisally, there is the lingual portion of the incisal ridge. Between this ridge and the marginal ridges and the cingulum, a shallow concavity called "the lingual fossa" is present (usually have developmental grooves).

3. Mesial Aspect:

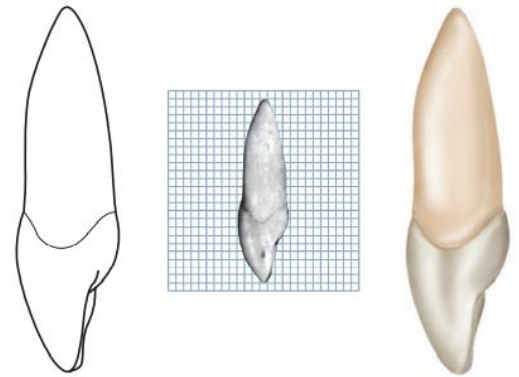
1. The crown is triangular in shape, with the base at the cervix and the apex at the incisal ridge.

2. A line which bisects the crown will bisect the root.

3. The labial outline is slightly convex.

4. The lingual outline of the crown is convex at the cingulum, then becomes concave at the mesial marginal ridge, then slightly convex at the incisal ridge.

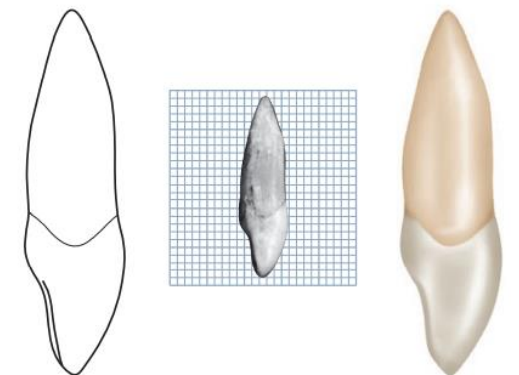
5. The cervical outline curves incisally more than any surface on any tooth, about 3-4 mm.



4. Distal Aspect:

There is little difference between distal and mesial outlines.

The curvature of the cervical line is less distally than mesially.



5. Incisal Aspect:

1. The incisal edge is centered over the root.


2. The labial outline of the crown is broad and flat.

3. The incisal edge and incisal ridge are well-defined.

4. The outline of lingual part tapers lingually to the cingulum.

5. The mesio-distal dimension labially is greater than that lingually.

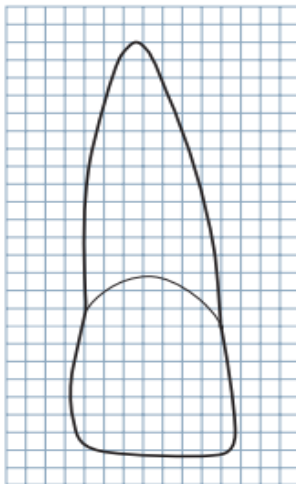
6. The crown has triangular shape, as the root shape in cross-section.



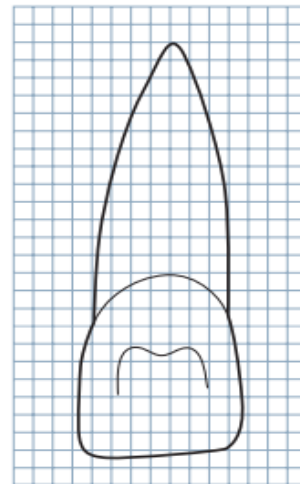
Measurements and drawing of the maxillary central incisor

MEASUREMENT TABLE								
	CERVICOINCISAL LENGTH OF CROWN	LENGTH OF ROOT	MESIODISTAL DIAMETER OF CROWN	MESIODISTAL DIAMETER OF CROWN AT CERVIX	LABIO- OR BUCCOLINGUAL DIAMETER OF CROWN	LABIO- OR BUCCOLINGUAL DIAMETER OF CROWN AT CERVIX	CURVATURE OF CERVICAL LINE—MESIAL	CURVATURE OF CERVICAL LINE—DISTAL
Dimensions* suggested for carving technique	10.5	13.0	8.5	7.0	7.0	6.0	3.5	2.5

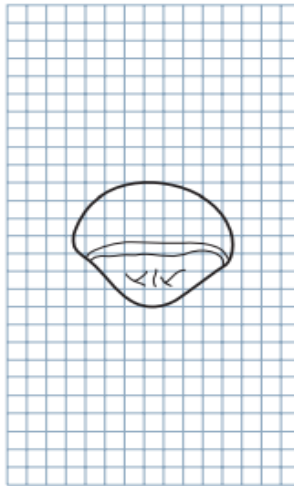
*In millimeters.



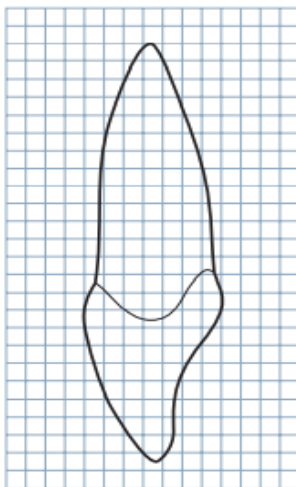
Labial



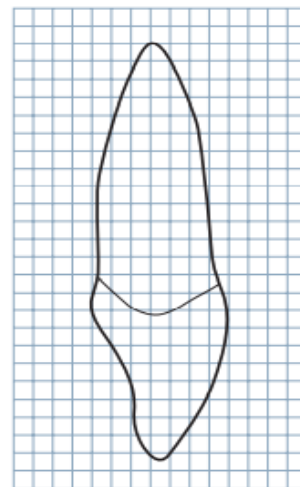
Lingual



Incisal



Mesial



Distal